

Bilaterally Elongated Styloid Process – A Case Report

RAJAN KUMAR SINGLA, BHAGYA SHREE, RAVI KANT SHARMA

ABSTRACT

The styloid process is a long cylindrical process arising from the temporal bone. It is usually 20-30 mm long. If it is more than 30 mm long, it is said to be elongated styloid process. It may be due to ossification of stylohyoid ligament and may be unilateral or bilateral. The material for the present study comprised of a skull prepared in the Department of Anatomy, Govt. Medical College, Amritsar after routine undergraduate dissection. The styloid processes in the said

skull were elongated on both the sides, the length being 76 mm on right and 71 mm on left side. These were fused with the hyoid bone at site of lesser cornua. A knowledge of such variation may be of interest not only for anatomist but also for physicians and surgeons. An elongated styloid process may be responsible for different sets of clinical features like cervicofacial pain or feeling of foreign body in pharynx. These may be attributed to compression of some neural or vascular structure by it.

Keywords: Styloid process, Skull, Stylohyoid ligament

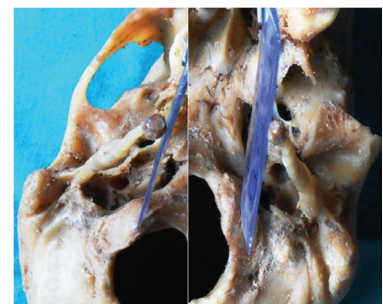
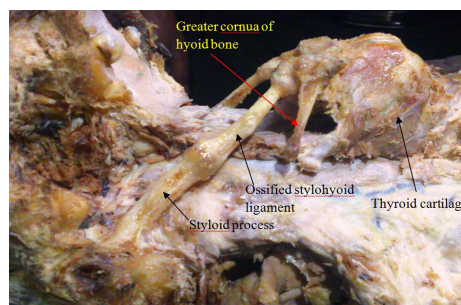
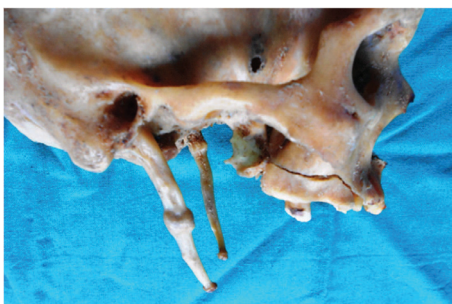
INTRODUCTION

Styloid process of temporal bone is a long, cylindrical, bony projection attached to the base of the skull and extends downwards, forwards and slightly medially. It gives attachment to the muscles and ligaments which have a role in mastication and swallowing [1]. One of these ligaments, the stylohyoid ligament passes downwards and forwards from its extremity to the lesser horns of the hyoid bone [2]. Usually the styloid process is 20- 30 mm long [3]. If it is > 30 mm long, it is said to be elongated styloid process. It may be due to ossification of stylohyoid ligament and may be unilateral or bilateral [1].

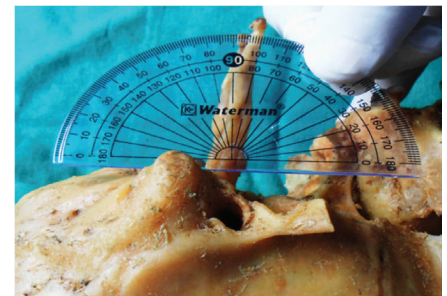
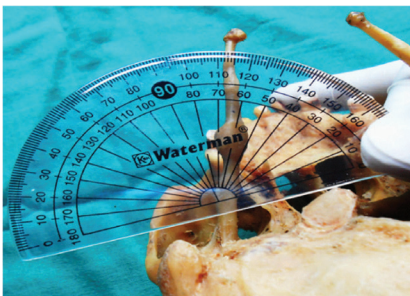
Elongation of styloid process and or ossification of stylohyoid ligament may result in styloid stylohyoid syndrome which is also known as Eagle syndrome, elongated styloid process syndrome, styloid process- carotid artery syndrome, stylohyoid syndrome or styloid process neuralgia [4].

According to Kim et al [5] the elongation was 1st described in 1652 by an Italian surgeon Marchetti and Eagle [6] coined the

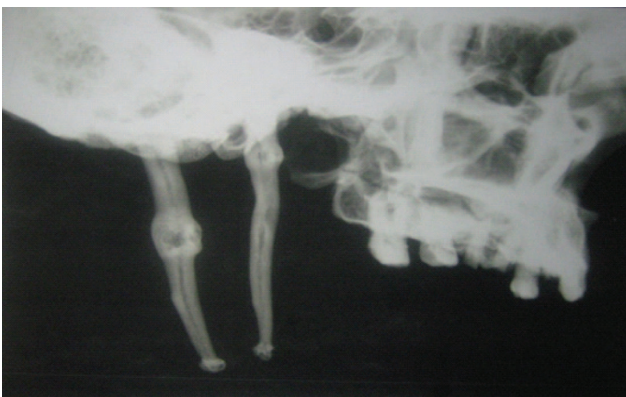term stylalgia to describe the pain associated with elongation of styloid process. He primarily described the two types of syndrome associated with elongated styloid process in 4% of population and stressed that not all cases of elongation are symptomatic [7]. The classic styloid syndrome is usually seen after tonsillectomy as pharyngodynia localised in the tonsillar fossa, sometimes with dysphagia, odynophagia, hypersalivation, foreign body sensation and more rarely by temporary voice changes, all of which presumably occur when tightened tonsillectomy scar tissue moves across the tip of the elongated styloid process during functional movements. The stylo-carotid syndromes (Carotidynia and Ernst syndrome) are due to compression of the internal and /or the external carotid arteries and especially their perivascular sympathetic fibers, resulting in a persistent pain radiating to the carotid territory, as headache, chronic neck pain, pain upon turning the head and pain radiating to the eye. Ear pain and vertigo are other possible complaints. Patients with any of these clinical manifestations may thus present to dental, otorhinolaryngology,



[Table/Fig-1]: Bilaterally elongated styloid process **[Table/Fig-2]:** Fusion of styloid process with hyoid bone at site of lesser cornua **[Table/Fig-3]:** Medial extent of tips of two styloid processes



[Table/Fig-4]: Measurement of angle on medial side between long axis of right styloid process and base of skull **[Table/Fig-5]:** Measurement of angle on medial side between long axis of left styloid process and base of skull **[Table/Fig-6]:** Measurement of angle on anterior side between long axis of styloid process and base of skull



[Table/Fig-7]: Radiograph of the two styloid processes

ophthalmology or neurosurgery department with a plethora of complaints [8].

Earlier many reports on elongated styloid process have been published but such long and thick styloid process and that too on both the sides is rarest of the rare anomalies, so is being reported in this article.

CASE REPORT

During the routine preparation of skulls in the department of anatomy we came across a skull which had enormously elongated styloid process with ossified stylohyoid ligament on both the sides [Table/Fig-1]. On right side, its total length from lower margin of tympanic plate upto tip of styloid process was 76 mm. At base its anteroposterior diameter was 8 mm and transverse diameter was 6 mm. At a distance of 36 mm from base there was a swollen area of length 8 mm, AP diameter 12 mm and transverse diameter 7 mm. Then its diameters decreased towards tip and the minimum diameters just before its tip were 4 mm X 2 mm. At the tip the styloid process again dilated to the diameters 6 mm X 4 mm. It has been described in the report that the first swelling at the distance of 36 mm from the base could be the site of fusion between actual styloid process and stylohyoid ligament since the stylohyoid ligament is ossified in this specimen, it could not be seen as a ligament. Thus the proximal 36 mm represented the actual styloid process and distal part represented the ossified stylohyoid ligament. The apical dilatation represented the

Types	Nomenclature	Radiographic Appearances
I	Elongated	Uninterrupted integrity of styloid image (>25- 28mm)
II	Pseudo-Articulated	Styloid process is joined to the mineralised stylomandibular or stylohyoid ligament by a single pseudo articulation, usually located superior to inferior border of the mandible.
III	Segmented	Short or long continuous portions of the styloid process or uninterrupted segments of mineralized ligament.

[Table/Fig-8]: Morphological Characteristics of Styloid Process

Patterns	Radiographic Appearances
Calcified Outline	Thin radiopaque cortex and a central lucency that constitutes most of the process
Partially Calcified	Thicker radiopaque outline with almost complete opacification as well as small and occasionally discontinuous radiolucent core.
Nodular Complex	Knobby or scalloped outline which may be partially calcified with varying degree of central radiolucency.
Completely Calcified	Totally radiopaque with no evidence of radiolucent interior.

[Table/Fig-9]: Patterns of Calcifications

site of fusion between stylohyoid ligament and lesser horn of hyoid bone. This has been shown in the [Table/Fig-2], where the distal end of ossified stylohyoid ligament thus fused with the hyoid bone at the site of lesser horn.

On the left side, the total length of the styloid process was 71 mm from lower margin of tympanic plate upto tip of styloid process. At base the AP diameter was 7 mm and transverse diameter was 5 mm. But on this side, at a distance of just 5 mm from base, a swelling representing site of fusion between styloid process and ossified stylohyoid ligament was seen. It had 6 mm length, 12 mm anteroposterior diameter and 6 mm transverse diameter. Thereafter the styloid process decreased in its thickness till just before the tip where it was 4 mm anteroposteriorly and 2 mm transversely thick. Then again at the

tip it dilated to 6 mm X 4 mm. The distance between the inner edges of tips of the 2 styloid process was only 26 mm. A vertical line extended upwards from the inner edge of the tip of right styloid process was touching the base of skull at medial margin of occipital condyle near its anterior end. A similar line on left side touched approximately the middle of occipital condyle [Table/Fig-3]. Thus the tips of the two elongated styloid processes were coming in line with articular facets of the cervical vertebrae or were in close apposition with them.

On both the sides the angle between long axis of styloid process and base of skull was 68° [Table/Fig-4,5] on medial side and 80° on anterior side [Table/Fig-6]. Thus these were tilted by 68° medially and 80° anteriorly.

On radiological examination, right styloid process had a thick ossified cortex from base till tip with a central thin non-ossified canal. Even at junction of styloid process and ossified stylohyoid ligament there was a swelling which represented pseudoarthrosis because of translucent space in it. On the left side also the cortex was thick and ossified with a central thin non ossified canal. However on this side, the canal was interrupted at places. The junction between styloid process and ossified stylohyoid ligament had a very thin cavity [Table/Fig-7].

DISCUSSION

Massey [9] found only 11 cases of an elongated styloid process out of 2000 cases. On the contrary, Rastrepo et al [10] estimated that 4% of the population might be having an elongated styloid out of which only 4-10% would be symptomatic. Cawich et al [11] claimed that elongated styloid process is seen 4 times more in males than in females and 75% of cases of elongation are usually bilateral. In spite of all these reports, the present case is unique being bilaterally elongated styloid process with length > 70 mm.

Langlais et al [12] proposed a radiographic classification of elongated and mineralised stylohyoid ligament complex based on types of elongation and patterns of calcification of stylohyoid ligament are shown in [Table/Fig-8,9].

Accordingly, the right as well left styloid processes fit into type II with partially calcified pattern.

ONTOGENY

There have been various attempts at explanation of its pathogenesis, which remains debatable. According to Steinmann [13], ossified stylohyoid ligament is a congenital anomaly.

The cartilage of the second pharyngeal or hyoid arch (Reichert's cartilage) gives rise to the stapes, styloid process, stylohyoid ligament, lesser horn and upper part of the body of hyoid bone [14]. The stylohyoid chain components are derived embryologically in four distinct segments: tympanohyal, stylohyal, ceratohyal and hypohyal segments. These segments are derived from Reichert's cartilages that ossify in two parts. The styloid process develops from tympanohyal and stylohyal segments that usually fuse at puberty. The lesser horn of the

hyoid bone arises from the hypohyal segment. Connecting these two structures, the stylohyoid ligament originates from the ceratohyal segment [15].

Actual cause of elongation is poorly understood. Several theories are proposed:

1. Congenital elongation due to persistence of a cartilaginous anlage in the stylohyal.
2. Calcification of the stylohyoid ligament by an unknown cause.
3. Growth of Osseous tissue at the insertion of the stylohyoid ligament.

Murtagh et al., [16]

CLINICAL IMPLICATIONS

An elongated styloid process usually remains asymptomatic but has also been linked with Eagle's syndrome known as styloid stylohyoid syndrome, elongated styloid process syndrome, styloid process carotid artery syndrome, stylohyoid syndrome or styloid process neuralgia [4]. It is characterised by sensation of having a foreign body in pharynx causing dysphagia, odynophagia and earache. There may be nagging or aching sensation in throat similar to chronic pharyngitis [7]. It can also cause vertigo, tinnitus, dysphonia, carotidynia, pain on turning the head, decreased mandibular opening, change in voice, hypersalivation and alteration in taste [15]. It is the direction and curvature of styloid process which are more important than its length in causing symptoms [17]. Diagnosis can usually be made by digital palpation of styloid process in tonsillar fossa which increases the pain. Also relief of symptoms with injection of anaesthetic solution into tonsillar fossa is highly suggestive of this diagnosis [18].

The pathophysiological mechanism of symptoms is not very clear. However following theories are proposed.

- i. Traumatic fracture of styloid causing proliferation of granulation tissue, which compresses the adjacent structures.
- ii. Compression of adjacent nerves, glossopharyngeal, lower branch of trigeminal or chorda tympani.
- iii. Stylohyoid insertion tendonitis.
- iv. Irritation of pharyngeal mucosa by direct compression or post tonsillectomy scarring.
- v. Impingement of carotid vessels, producing irritation of sympathetic nerves in the arterial sheath.

Kolagi et al., [2]

- vi. Mucopolysacchridosis and diffuse idiopathic skeletal hyperostosis.
- vii. Endocrinal disorders in postmenopausal women.
- viii. Malformation of styloid apparatus associates with malformation of atlanto occipital hinge.

Fini et al., [19]

Differential diagnosis in patients with similar symptomatology include temporomandibular joint diseases, trigeminal, sphenoid

nopalatine or glossopharyngeal neuralgias, temporal arteritis, chronic pharyngotonsillitis, otitis media, external otitis, mastoiditis, dental pain, improperly fitting dental prostheses, submandibular sialadenitis or sialolithiasis, true pharyngeal foreign bodies and tumors of the pharynx or tongue base etc [20], laryngopharyngeal dysesthesia, temporomandibular arthritis, hyoid bursitis, sluder's syndrome, histamine cephalgia, cluster type headache, esophageal diverticula, cervical vertebral arthritis and migraine- type headache should also be considered [21].

Treatment of such cases may be conservative or surgical. Former includes antiepileptics, antihistaminics, vasodilators, neuroleptics, antidepressants and tranquilizers [22]. Injection of corticosteroids diluted in local anaesthetic close to styloid process is another alternative and is diagnostic as well as palliative [8]. Surgical removal has been described both intraorally as well as extraorally but there are reports of recurrence of symptoms postoperatively, questioning the benefits of surgical technique [23].

REFERENCES

- [1] Gokce C, Sisman Y, Tarim Ertas E, Akgunlu F, Ozturk A. Prevalence of styloid process elongation on panoramic radiography in the Turkey population from Cappadocia region. *Eur J Dent* 2008; 2: 18-22.
- [2] Kolagi SI, Herur A, Mutalik A. Elongated styloid process- report of two rare cases. *Inter J Anat Variat* (2010) 3:100-2.
- [3] Sokler K, Sandev S. New classification of the styloid process length--clinical application on the biological base. *Coll Anthropol* 2001; 25: 627-32.
- [4] Langlais RP, Miles DA, Van Dis ML. Elongated and mineralized stylohyoid ligament complex: A proposed classification and report of a case of Eagle's syndrome. *Oral Surg Oral Med Oral Pathol* 1986; 61: 527-32.
- [5] Kim E, Hansen K, Frizzi J. Eagle syndrome: case report and review of literature. *Ear Nose Throat J*. 2008; 87: 631- 633.
- [6] Eagle WW: Elongated styloid process: Report of two cases. *Arch Otolaryngol* 1937; 25: 584-87.
- [7] Eagle WW. Symptomatic elongated styloid process: Report of two cases of styloid process- carotid artery syndrome with operation. *Arch Otolaryngol* 1949; 49: 490- 503.
- [8] Palesy P, Murray GM, de Boever J, Klineberg I. The involvement of the styloid process in head and neck pain- A preliminary study. *J Oral Rehabil*. 2000; 27: 275- 87.
- [9] Massey EW. Facial pain from an elongated styloid process (Eagle's syndrome). *South Med J*. 1978; 71: 1158- 59.
- [10] Restrepo S, Palacios E, Rojas R. Eagle's syndrome- Imaging Clinic. *Ear Nose Throat J* Oct 2002. http://findarticles.com/p/articles/mi_m0BUM/is_10_81/ai_93916091 (accessed December 10th 2009).
- [11] Cawich SO, Gardner M, Shelly R, Harding HE. A post mortem study of elongated styloid processes in a Jamaican population. *The Inter J Biol Anthropol*. 2008; Volume 3: Number 1. Cited by: Kolagi SI, Herur A, Mutalik A. Elongated styloid process- report of two rare cases. *Inter J Anat Variat*. (2010) 3:100-02.
- [12] Langlais RP, Langland OE, Nortje CJ. Soft tissue radiopacities Chapter 19. Diagnostic imaging of the jaws. *Philadelphia: A Lea and Febiger*. 1995. p. 617- 21.
- [13] Steinmann EP. Styloid syndrome in absence of an elongated process. *Acta Otolaryngol*. 1968; 66: 347-56.
- [14] Sadler TW. Head and Neck. In: Langman's Medical Embryology. 11th ed. *Philadelphia, London: Lippincott Williams & Wilkins*; 2010: p. 269.
- [15] Rodriguez-Vazquez JF, Merina-Velasco JR, Verdugo- Lopez S, Sanchez- Mantecinos I, Merida-Velasco JA. Morphogenesis of the second pharyngeal arch cartilage (Reichert's cartilage) in human embryos. *J. Anat*. 2008; 208: 179- 89.
- [16] Murtagh RD, Carcciolo JT, Fernandez G. CT findings associated with eagle syndrome. *Am J Neuroradiol*. 2001; 22: 1401-02.
- [17] Frommer J. Anatomic variations in the stylohyoid chain and their possible clinical significance. *Oral Surg*. 1974; 38: 659- 87.
- [18] Balbuena L, Hayes D, Ramirez SG, Johnson R. Eagle's syndrome (elongated styloid process). *South Med J*. 1997; 90: 331-34.
- [19] Fini G, Gasparini G, Filippini F, Becelli R, Marcotullio D. The long styloid process syndrome or Eagle's syndrome. *J Craniomaxillofac Surg*. 2000; 28: 123-27.
- [20] Beder E, Ozgursoy OB, Ozgursoy SK. Current diagnosis and transoral surgical treatment of Eagle's syndrome. *J oral Maxillofacial Surg*. 2005; 63: 1742- 45.
- [21] Savranlar A, Uzun L, Ugur MB, Ozer T. Three dimensional CT of Eagle's syndrome. *Diagn Interv Radiol*. 2005; 11: 206- 09.
- [22] Gervickas A, Kubilius R, Sabalys G. Clinic, diagnostics and treatment peculiarities of Eagle's syndrome. *Stomatol Balt Dent Maxillofac J*. 2004; 6:12-13.
- [23] Jain S, Bansal A, Paul S, Prashar DV. Styloid- Stylohyoid syndrome. *Ann Maxillofac Surg*. 2012; 2(1): 66-69.

AUTHOR(S):

1. Dr. Rajan Kumar Singla
2. Dr. Bhagya Shree
3. Dr. Ravi Kant Sharma

PARTICULARS OF CONTRIBUTORS:

1. Additional Professor, Department of Anatomy, Govt. Medical College, Amritsar, Punjab, India.
2. Senior Resident, Department of Anatomy, Guru Gobind Singh Medical College, Faridkot, Punjab, India.
3. Professor & Head, Department of Anatomy, Govt. Medical College, Amritsar, Punjab, India.

NAME, ADDRESS, E-MAIL ID OF THE CORRESPONDING AUTHOR:

Dr. Bhagya Shree,
Senior Resident, Department of Anatomy, Guru Gobind Singh Medical College, Faridkot-151203; Punjab, India.
Phone : 09463364664
E-mail: drashwinibhagya@yahoo.com

FINANCIAL OR OTHER COMPETING INTERESTS:

None.

Date of Publishing: Sep 01, 2014